

Activity Test of Lime Peel Extract Nanoemulsion Preparation (*Citrus Aurantifolia*) on Reducing SGOT-SGPT Levels, Assessment of Necrosis, Fibrosis and Liver Lobules in Wistar Rats (*Rattus Norvegicus*) Streptozotocin-Induced

Chita Wijayasari¹, Chrismis Novalinda Ginting², Linda Chiuman³

^{1,2,3}Faculty of Medicine, Universitas Prima Indonesia, Medan, Indonesia

*E-mail : dr.chiwi@gmail.com

ABSTRACT

In humans, the liver is an organ involved in various processes important for life. Insulin resistance can lead to chronic liver damage, such as cirrhosis and liver failure. SGOT and SGPT are two enzymes produced by liver cells and used to assess liver function. Elevated SGOT and SGPT levels can be caused by hepatitis, fatty liver disease, gallbladder obstruction, and other diseases. This study was conducted to see how the activity of lime peel extract nanoemulsion preparation (*Citrus aurantifolia*) reduces SGOT-SGPT levels, assesses the level of necrosis, fibrosis and liver lobules in rat strains (*Rattus Norvegicus*) streptozotocin-induced. A sample of 25 mice in 4 groups (control, treatment 1, 2, and 3) where the extract preparation in the treatment was in the form of nanoemulsion of lime peel extract (*Citrus aurantifolia*) at concentrations F1 (1%), F2 (1.5%) and F3 (2%). The results observed in Diabetes mellitus can cause liver dysfunction. And Lime peel (*Citrus aurantifolia*) extract nanoemulsion is effective for treating liver function in diabetic rats and the effective extract concentration sequence is F3 (2%), F2 (1.5%) and F1 (1%).

Keywords: Lime Peel, Nanoemulsion, Liver, SGOT-SGPT, Diabetes.

INTRODUCTION

Unhealthy lifestyles include infrequent or no exercise, smoking, and lack of sleep. Fast food is high in sodium and fat, but stressed people tend to overconsume junk food or fast food. Both of these foods can lead to various health problems. For example, too much sodium can lead to high blood pressure and heart attacks. On the other hand, obesity can lead to diabetes and other chronic diseases. (Makarim, 2024).

In humans, the liver is an organ involved in various processes essential for life. It produces plasma proteins such as albumin, tightly regulates blood plasma composition, controls the flow of energy and nutrients within tissues, and is involved in detoxification and waste excretion. Because of its vital functions in the human body, it is important to accurately assess liver injury and malfunction. (Ozougwu, 2017) The liver is also a major site of metabolism for endogenous and exogenous substances (e.g., drugs and toxins). This process, known as biotransformation, converts lipophilic substances into hydrophilic ones for subsequent elimination (Yip et al., 2021). Excessive levels of toxic substances in the liver can cause various types of liver damage, such as liver degeneration and necrosis. Hepatocyte damage is a serious problem for people with type 2 diabetes mellitus. Insulin resistance,

which increases oxidative stress and activates inflammatory signals, can lead to liver damage. Insulin resistance can lead to chronic liver damage, including cirrhosis and liver failure.(Pouwels et al., 2022).

The purpose of this liver function test is to determine the overall condition of the liver and the possibility of liver disease. SGOT and SGPT are two types of enzymes produced by liver cells and are used to assess liver function. Normal SGOT levels are 3-45 μ /L (micro per liter), while normal SGPT levels are 0-35 μ /L. Elevated SGOT and SGPT levels can be caused by hepatitis, fatty liver disease, gallbladder obstruction, and other diseases.(Mochamad Rizal, 2022)Due to insulin resistance and impaired glucose uptake by tissues, the liver increases the breakdown of glycogen into glucose, which can lead to hyperglycemia. Several subsequent mechanisms, including inflammation, necrosis, and fibrosis in the liver in 2-3% of NAFLD patients, increase liver damage, leading to non-alcoholic steatohepatitis (NASH). Bleeding and fibrosis in NASH can lead to cirrhosis and hepatocellular carcinoma (HCC), which can lead to liver failure.(Mehta BK, 2017)Glucose requires insulin to transport glucose from the bloodstream throughout the body to perform its functions. When the body absorbs carbohydrates, the pancreas triggers an insulin response to enter the bloodstream to absorb the glucose for energy, resulting in a decrease in blood glucose levels.(Emy Oktaviani, Lusi Indriani, 2022).

Herbal medicine can be an alternative treatment, especially for hyperglycemia. Traditional herbal remedies can enhance and improve gene expression in the body. Phenolic and flavonoid compounds in medicinal plants can lower blood sugar levels, thus having anti-diabetic effects.(Linda Wati, Linda Chiuman, Ali Napiyah Nasution, 2021)One plant that has potential for diabetes is lime (*Citrus Aurantifolia*). Not only that, the vitamin C in limes can also help lower blood sugar levels.(Ade Maria Ulfa, Nofita, 2020). In limes, especially in the peel, there are essential oils, flavonoids, alkaloids, and saponins which consist of various substances such as terpenes, sesquiterpenes, aldehydes, esters, and sterols.(Ade Maria Ulfa, Nofita, 2020). It is also knownPhytochemical results from lime leaf extract plants prove the presence of various secondary metabolic compounds, namely flavonoids, alkaloids, and saponins, where these compounds act as antihyperglycemics.(Loizzo, 2012). With the advancement of technology in the medical field, nanoemulsions represent a new breakthrough in the delivery of medicines.The nanoemulsion extract is presented because the smaller flavonoid particles have the potential for higher antidiabetic activity. This preparation can increase the effectiveness of drug therapy and minimize side effects and toxic reactions.

Based on this background, the researcher is interested in conducting research with the title "Activity of lime peel extract nanoemulsion preparation (*Citrus aurantifolia*) on reducing SGOT-SGPT levels, assessment of necrosis, fibrosis and liver lobules in rat strains(*Rattus Norvegicus*)streptozotocin-induced".

LITERATURE REVIEW

Streptozotocin (STZ) is a synthetic derivative of nitrosourea glucopyranose produced by the fermentation of *Streptomyces achromogenes*, which is a broad-spectrum antibiotic that fights tumors. Chemically, streptozotocin interacts with other nitrosoureas used in cancer chemotherapy. STZ is a cancer chemotherapy drug that helps prevent DNA synthesis, induces cell death, and prevents cell regeneration. In addition, STZ inhibits insulin secretion, which causes insulin-dependent diabetes mellitus.(Coskun et al., 2005).

High blood sugar levels, also known as glucose, are a chronic condition known as diabetes mellitus, also often referred to as diabetes. The body's cells normally absorb glucose with the help of the hormone insulin to convert it into energy, controlling blood glucose levels.(Cerner, 2020).

The liver is an important organ of the body that is responsible for the metabolism of toxic substances, This can cause the liver to often become a target for toxins, this is caused because toxic substances enter the body through the gastrointestinal system which is then absorbed and carried by the portal vein to the liver.(Huda MN, 2017).If the liver is not functioning, a person cannot survive more than a day(Virani et al., 2020). Non-alcoholic fatty liver disease or non-alcoholic fatty liver disease (NAFLD) is a condition characterized by excessive accumulation of fat in liver cells or hepatocytes.(Brunt EM, Wong VW, Nobili V, Day CP, Sookoian S, Maher JJ, 2015)Serum Glutamic Pyruvate Transaminase (SGPT), also known as ALT (Alanine Aminotransferase), is an enzyme found in liver cells. Like SGOT, when liver cells are damaged, the SGPT enzyme is released into the bloodstream. Elevated SGPT levels can be detected through a laboratory blood test.(MD & MD, 2014).

Limes (*Citrus Aurantifolia*) are a plant that has been used since ancient times as a traditional medicine and food additive. Limes are a good fruit for people with diabetes. Limes contain many nutrients, including vitamin C, vitamin A, and potassium. They also have antioxidant and antibacterial properties, which help maintain healthy skin, boost the immune system, and prevent heart disease.(Narareba, 2023).

METHODS

This study uses a quantitative experimental research type, namely by using a true experiment or laboratory experimental design where this study was conducted to test the activity of lime peel extract nanoemulsion preparations (*Citrus aurantifolia*) on reducing SGOT-SGPT levels, assessing the level of necrosis, fibrosis and liver lobules in male rats induced by streptozotocin.The research design uses a post-test with control group design or controls the sample based on the treatment group.*post test*was carried out to see the success of the extract in reducing serum SGOT and SGPT in mice that have beeninduced by streptozotocin, then histopathological observations of the livers of rats in each treatment group were carried out by assessing the level of necrosis, fibrosis and liver lobules in male rats induced by streptozotocin.

The sample of this study was male Wistar rats (*Rattus norvegicus*) weighing 160-250 grams and aged 2-3 months. The number of test animals was 4 per group. In this study, researchers used 20 Wistar rats for each experimental group. The test animals were acclimatized for 7 days in the laboratory of the Department of Pharmacology and Therapeutics, Faculty of Medicine, University of North Sumatra. The preparation of lime peel extract nanoemulsion using the steam distillation method and made into nanoemulsion preparations whose particles were adjusted where the size of the nanoemulsion particles was carried out using a Particle Size Analyzer (Horiba Scientific, Nanoparticle Analyzer SZ-100). Treatment was given to treatment groups 1, 2, and 3 using the concentration of lime peel extract nanoemulsion preparations.concentrations of F1 (1%), F2 (1.5%), and F3 (2%).Method of administering extract to samples using a gastric tube. On examinationLiver function is seen from the levels of SGOT and SGPT in the liver as seen from the results of blood sample tests on STZ-induced mice. For histopathological description of the liver of mice using liver observation and seeing the NAFLD score and the level of necrosis in the liver of mice using 400x magnification myxopsis. For blood glucose measurement of mice using a blood

glucose meter with Easy Touch GCU taken through the tail of the mouse. Data from the research results were tabulated and analyzed with the help of SPSS (Statistics of Package for Social Science) 25.0. for windows.

RESULT

A nanoemulsion preparation of lime peel extract was successfully formulated using the spontaneous emulsification method followed by sonication for 10 minutes. The results showed that this formulation produced an emulsion with a particle size of <200 nm and was visually stable after 14 days of storage. Characterization testing then continued, with the following results:

Table 1. Characterization Test Results

Parameters	Test Results	Information
Particle size	115.4 nm (± 10 nm)	Particle size shows nanoscale <200 nm \rightarrow nanoemulsion category
pH	5.6	Safe enough for topical (skin) or oral application
Visual stability	Stable for 14 days, no phase separation	Nocreaming, coalescence, or flocculation occurs
Color	Pale yellow	According to the character of lime extract
Aroma	Fresh, typical orange, slightly sour	Indicates that volatile compounds are still active

And continued with phytochemical testing, where the results Studies have shown that lime peel extract (*Citrus Aurantifolia*) contains active compounds such as alkaloids, flavonoids, saponins, tannins, steroids, and triterpenoids. Therefore, this extract offers numerous health benefits due to its antioxidant properties, which can be used as an antidiabetic and anticancer agent.

This study was conducted to analyze its conclusions. This chapter contains data along with an explanation of the research results in testing and analyzing the preparation of lime peel extract nanoemulsion (*Citrus aurantifolia*) on reducing SGOT-SGPT levels, assessing the level of necrosis, fibrosis and liver lobules in male rats induced by streptozotocin. This study used male rats (*Rattus norvegicus*) of the Wistar strain weighing 160-250 grams and aged 2-3 months with a total of 24 Wistar rats for each experimental group. The grouping of test animals was carried out randomly into 4 test groups with 6 rats each, namely the control group, treatment group 1, treatment 2 and treatment 3.

On day 0, the mice's KGD (blood glucose level) was calculated as the initial sugar level before being induced by alloxan. All groups of mice will be induced with streptozotocin at a dose of 50 mg/kgBW by injection 3 times a week via intraperitoneal and their blood sugar levels will be calculated which are listed in the table as day 14. Monitoring the body weight of mice in groups P0, P1, P2, P3 on day 0 as the initial day, then day 14 as the day after being given diabetes induction and day 28 as the day after being given lime extraction with concentrations of 1%, 1.5% and 2%. The following is the graph:

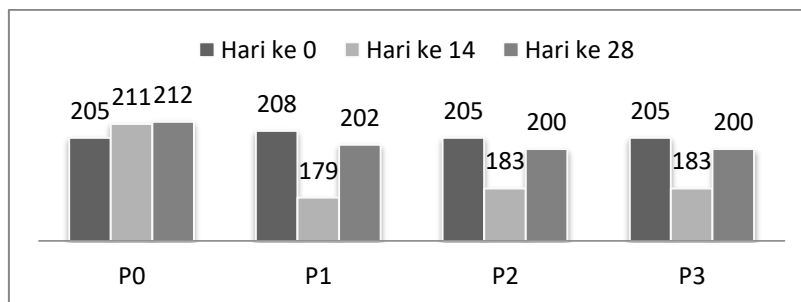


Figure 1. Body Weight Graph (gr) in Rats

Furthermore, blood glucose levels (BG) were monitored in mice. Mice exhibit hyperglycemic glucose levels if the glucose levels are ≥ 300 mg/DL. Then, groups of mice P1, P2, and P3 were given lime peel (*Citrus aurantifolia*) nanoemulsion treatment at concentrations of 1%, 1.5%, and 2% for 14 days. On the 28th day, the glucose levels of the mice, including those of the control group (P0), were re-examined. Data presentation uses the following table:

Table 2. Average Blood Glucose (KGD)mg/dL

Group	Day - 0	Day - 14	Day - 28
P0	93	94.5	96.8
P1	96.16	327	125
P2	97	331	96.3
P3	94.6	329.8	83

Reporting Research Results

After observing the body weight and blood glucose of the mice, liver function was then observed. The normal range of SGPT values in mice is 17.5-30.2 (IU/L), while the normal range of SGOT values in mice is 45.7-80.8 (IU/L). Observations were made on the 14th day after diabetes induction and the 28th day after lime peel extract treatment. The following are the results of observations of the mice's liver function:

Table 3. Average SGOT(U/L)and SGPT(U/L)

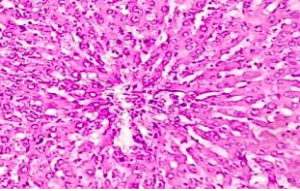
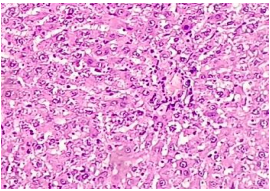
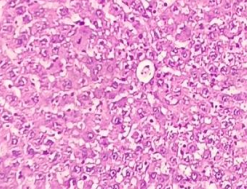
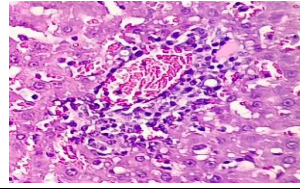
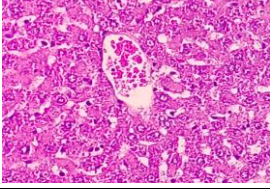
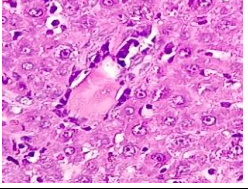
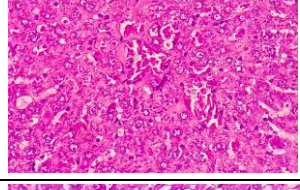
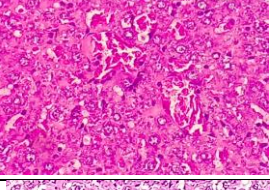
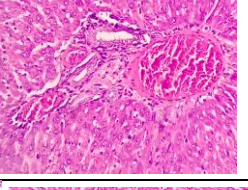
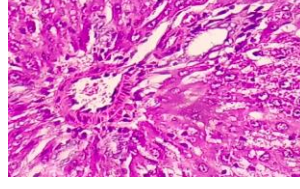
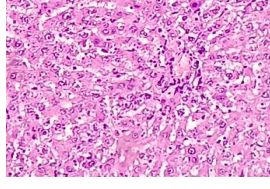
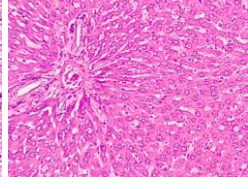
Group	Induction - Day 14		Extraction - Day 28	
	SGOT	SGPT	SGOT	SGPT
P0	63±8.43	23.5±2.7	64.3±7.7	25±2.75
P1	203.5±26.6	105.5±6.9	97.5±9.3	34.3±2.9
P2	204.3±16.5	107.1±7.8	80.67±8.9	24.8±2.48
P3	193.8±13.6	105.3±9.9	51.5±5.9	19.5±1.8

Group P0 is the reference group because it was not given streptozotocin and was only given standard feed. The table above shows that the streptozotocin-induced rat groups P1, P2, and P3 showed an increase above normal values on day 14, with the highest mean and standard deviation of SGOT values in group P2, namely 204.3±16.5 and SGPT values 107.1±7.8. And after 14 days of administration nanoemulsion of lime peel extract (*Citrus aurantifolia*) given, in group P1 showed the average SGOT results 97.5±9.3 and the SGPT results are 34.3±2.9 where the results are still above normal, so the liver function of

the mice has not reached normal limits when viewed from enzyme observations.. For group P2, the average SGOT results were shown, namely 80.67 ± 8.9 and the SGPT results are 24.8 ± 2.48 , so if we look at the results in this group, it has reached the normal limit value. In group P3 shows the average SGOT results, namely 51.5 ± 5.9 and the SGPT results are 19.5 ± 1.8 so that if we look at the results in this group, it has also reached the normal limit value.

The researchers then examined liver function at the level of necrosis, fibrosis, and liver lobules in streptozotocin-induced rats (*Rattus Norvegicus*) and described it through histopathological images of liver function to determine the impact of liver function on those with diabetes mellitus and treated with the extract. The results are as follows:

Table 4. Histopathology Results of Rat Liver

Group	Histopathological Image Results of Rat Liver Function		
Control (P0)			
Treatment (P1)			
Treatment (P2)			
Treatment (P3)			

From the histopathological observations above, in the control group (P0) the microscopic image of the liver of the Wistar rats in the control group (P0) did not show necrosis, no fibrosis. The structure of the liver lobules was normal and the radial arrangement of hepatocytes was regular. The microscopic image of the liver of the rats in treatment group 1 (P1) in this group showed focal and diffuse necrosis, especially around the central and portal veins. Mild to moderate periportal fibrosis was seen; sinusoidal dilation. The structure of the liver lobules was disorganized; the lobule boundaries were unclear. The microscopic image of the liver of the rats in treatment group 2 (P2) showed minimal necrosis and some vacuolization, but mild periportal fibrosis was seen but the lobule structure was more regular. The microscopic image of the liver of the rats in treatment group 3 (P3) showed no

visible necrosis, reduced fibrosis and a more regular lobule structure with an improved radial pattern of hepatocytes.

Then the data is analyzed to test whether there is a statistically significant difference between the two means from the same group, before and after treatment then use the test *Paired Sample t-Test* with the following results:

Table 5. Test Paired Sample t-Test

	Mean	t	df	Sig. (2-tailed)
SGOT (Induction – Extraction)	92,667	7,772	23	.000
SGPT (induction – extraction)	36,738	7,929	23	.000

The next step was to test whether there was a difference in the average liver function results of the four groups before and after the research treatment or observation. From the test results above, the significance value at a 95% confidence level ($p < 0.05$) was 0.00 for SGOT and SGPT liver function, so there was a significant difference in each average value between sample groups. Therefore, the conclusion obtained is that there is a significant difference in the average (mean) percentage of liver function of the three groups.

DISCUSSION

The liver is an important organ in the body that is responsible for the metabolism of toxic substances in the body (Salasam, et al 2015). In this case, the liver is often the target of toxins because toxic substances enter the body through the gastrointestinal system and are then absorbed and carried to the liver through the portal vein. (Huda MN, Holidah D, 2017). Having diabetes mellitus can lead to impaired liver function. Approximately three out of four people with type 2 diabetes, or prediabetes, have excessive fat in the liver. Liver fat triggers dangerous inflammation that can lead to cirrhosis. One way to detect liver damage is through a histopathological examination. This allows for visualization of altered morphology and histological structure, as well as the extent of liver damage. (Gibson, 2014).

This study used male wistar rats (*Rattus norvegicus*) weighing 160-250 grams and aged 2-3 months with a total of 24 wistar rats for each experimental group. The test animals were randomly divided into 4 test groups with 6 rats each, namely the control group, treatment group 1, treatment 2 and treatment 3. All groups of rats were induced with streptozotocin at a dose of 50 mg / kgBW by injection 3 times a week through intraperitoneal and their blood sugar levels were calculated as listed in the table as of day 14. In the phytochemical tests that have been carried out, it has been proven that lime peel extract (*Citrus Aurantifolia*) positively contains active compounds such as alkaloids, flavonoids saponins, tannins, steroids or triterpenoids. So it can be said that this extract has many health benefits because it contains antioxidants that can be used as antidiabetics and anticancer.

In monitoring blood glucose levels (KGD) in mice. Mice show hyperglycemic glucose levels if the level is ≥ 300 mg / dL. Then the groups of mice P1, P2, and P3 were treated with nanoemulsion of lime peel extract (*Citrus aurantifolia*) at concentrations of 1%, 1.5% and 2% for 14 days calculated on the 28th day the mice will have their glucose levels checked again including the control group (P0) which was not induced by streptozotocin and was not given the extract. On the 14th day after streptozotocin induction, the average results for each group were P0 with results of 94.5 mg / dL, P1 with results of 327 mg / dL, P2 with results of 331 mg / dL, and P3 with results of 329.8 mg / dL. The results showed that the average

blood glucose levels (KGD) in mice in groups P1, P2 and P3 were > 300 mg/dL. After being given nanoemulsion of lime peel extract (*Citrus aurantifolia*) visible group P1, P2, and P3 experienced decreased blood sugar levels and showed no signs of diabetes mellitus, with average results of 125 mg/dL, 96.3 mg/dL, and 83 mg/dL, respectively. The lowest result was in group P3, with a blood glucose level of 83 mg/dL. The results are below the P0 group as a reference. So the results of the mice's glucose levels returned to normal and Lime (*Citrus aurantifolia*) peel extract nanoemulsion was effective in lowering blood glucose levels in mice with diabetes mellitus. This is in line with research. (Suryadinata, 2023) In their research, lime peel extract effectively reduced blood glucose levels in alloxan-induced mice. A significant decrease ($p < 0.05$) was observed after 14 days of administration.

If we look at the research results, the scoring results for the histopathological observations of the livers of mice in group P0 with a score of 0, namely the overall observation of the liver organs looks normal, in group P1 with a scoring result of 3, namely the overall observation of the liver organs looks bad, namely bridging fibrosis is a form of advanced liver fibrosis, in groups P2 and P3 were given a score of 1, namely mild.

CONCLUSION

1. Results of secondary metabolite testing of phytochemical testing of lime peel extract (*Citrus aurantifolia*) positive for containing active compounds such as alkaloids, flavonoids, saponins, tannins, steroids or triterpenoids.
2. Liver function monitoring *Glutamic Oxaloacetic Transaminase* (SGOT) and *Glutamic Pyruvic Transaminase* (SGPT) in observations after streptozotocin induction were carried out, it was seen that the P1, P2 and P3 groups of mice showed an increase above normal values with the highest mean and standard deviation of SGOT in the P2 group, namely 204.3 ± 16.5 (U/L) and SGPT values 107.1 ± 7.8 (U/L). This shows that the body condition of diabetes mellitus can cause liver function disorders..
3. Histopathological observations of the liver in the control group (P0) showed no necrosis or fibrosis in the microscopic image of the rat liver. The structure of the liver lobules was normal, and the radial arrangement of hepatocytes was regular. In treatment group 1 (P1), focal and diffuse necrosis was observed, especially around the central and portal veins. Mild to moderate periportal fibrosis was observed; sinusoidal dilation was observed. The structure of the liver lobules was disorganized; the lobule boundaries were unclear. In treatment group 2 (P2), minimal necrosis and some vacuolization were observed, but mild periportal fibrosis was observed, but the lobule structure was more regular. In treatment group 3 (P3), necrosis was absent, fibrosis was reduced, and the lobule structure was more regular, and there was improvement in the radial pattern of hepatocytes. Thus, Lime peel (*Citrus aurantifolia*) extract nanoemulsion is effective for treating liver function in diabetic rats and the effective extract concentration sequence is F3 (2%), F2 (1.5%) and F1 (1%).

ACKNOWLEDGEMENT

With gratitude, the author would like to thank the Rector of Prima Indonesia University, the academic supervisor, parents and family, and also colleagues who have provided moral and material support in the preparation of this final assignment.

REFERENCES

- Ade Maria Ulfa, Nofita, BNB (2020). Blood Glucose Level Reducing Activity Test of Lime Peel Ethanol Extract (*Citrus Aurantifolia*) in Alloxan-Induced Male Sprague Dawley Rats. *MALAHAYATI PHARMACY JOURNAL*, 3(2), 126–138.
- Brunt EM, Wong VW, Nobili V, Day CP, Sookoian S, Maher JJ, D. (2015). Nonalcoholic fatty liver disease. *Nat Rev Dis Primers*, 1.
- Cerner. (2020). Diabetes Overview. *Drugs.Com*.
- Coskun, O., Kanter, M., Korkmaz, A., & Oter, S. (2005). Quercetin, a flavonoid antioxidant, prevents and protects streptozotocin-induced oxidative stress and β -cell damage in rat pancreas. *Pharmacological Research*, 51(2), 117–123. <https://doi.org/10.1016/j.phrs.2004.06.002>
- Emy Oktaviani, Lusi Indriani, HW (2022). Antidiabetic Glycemic Control Profile in Type 2 DM Patients with Liver Cirrhosis. *JMPF*, 12(1), 1–13.
- Huda MN, Holidah D, and FF (2017). Subchronic Toxicity Study of Jamu Asam Urat in Liver of Balb-C Mice. *Jurnal Pustaka Kesehatan*, 5(1), 65–70.
- Linda Wati, Linda Chiuman, Ali Napiah Nasution, CNG (2021). Anti-diabetic Activity of The Rose Petal Methanolic Extract in Alloxan-Diabetic Rats.
- Loizzo, D. (2012). Evaluation of *Citrus aurantifolia* peel and leaves extract for their chemical composition, antioxidant and anti-cholinesteraseactives. *Journal of the Science of Food and Agriculture*, 92(15), 2960–2967.
- Makarim, dr. FR (2024). Diabetes. *Halodoc*. www.halodoc.com
- MD, TAW, & MD, SAA (2014). Evaluation of abnormal liver tests. *Medical Clinics of North America*.
- Mehta BK, B.S. (2017). Characterization of Cognitive Impairment in Type 2 Diabetic Rats. *Indian J Pharm Sci*, 79.
- Mochamad Rizal, MK (2022). Risk Analysis of SGOT and SGPT Enzyme Levels in Type 2 Diabetes Mellitus Patients. *Medical Laboratory Journal*, 4(1).
- Narareba. (2023). The Secret Origins and Amazing History of Limes. *Narareba.Com*. <https://narareba.com/asal-usul-dan-sejarah-jeruk-nipis-citrus-aurantifolia/>
- NE, G. (2014). Hepatoprotective Effect of Ethanol Extract of Aloe Vera (*Aloe Vera* Linn.) on Histopathological Image of the Liver of Male White Rats (*Rattus Norvegicus*) Wistar Strain Induced by Paracetamol. *Journal of PSPD Students of FK Universitas Tanjungpura*, 3(1).
- Ozougwu, J. C. (2017). Physiology of the liver. *International Journal of Research in Pharmacy and Biosciences*, 4(8).
- Pouwels, S., Sakran, N., Graham, Y., Leal, A., Pintar, T., Yang, W., Kassir, R., Singhal, R., Mahawar, K., & Ramnarain, D. (2022). Non-alcoholic fatty liver disease (NAFLD): a review of pathophysiology, clinical management and effects of weight loss. *BMC Endocrine Disorders*, 22(1), 63. <https://doi.org/10.1186/s12902-022-00980-1>
- Salasam PYL, Setiasih NLE, and KIM (2015). The Effect of *Moringa oleifera* Bark Extract on Alloxan-Induced Histopathological Changes in the Liver of Wistar Rats. *Indonesia Medicus Veterinus*, 4(4), 332–341.
- Suryadinata, RV (2023). Changes in blood glucose levels in hyperglycemic experimental animals due to administration of lime peel extract (*Citrus aurantifolia* Swingle). *Indonesian Journal of Biotechnology and Bioscience (JBBI)*, 9(1), 139–146.
- Virani, SS, Alonso, A., Benjamin, EJ, Bittencourt, MS, Callaway, CW, Carson, AP, Chamberlain, AM, Chang, AR, Cheng, S., Delling, FN, Djousse, L., Elkind, MSV,

Ferguson, JF, Fornage, M., Khan, SS, Kissela, BM, Knutson, KL, Kwan, TW, Lackland, DT, ... Tsao, CW (2020). Heart disease and stroke statistics—2020 updated a report from the American Heart Association. In *Circulation* (Vol. 141, Issue 9). <https://doi.org/10.1161/CIR.0000000000000757>